

NOTES

ELECTROCARDIOGRAPHY (ECG)

ECG BASICS

osms.it/ECG-basics

- ECG traces provide information on heart's electrical activity, rate, rhythm
 - Depolarization waves moving towards electrode → positive deflection
 - Depolarization waves moving away from electrode → negative deflection
- 12 lead ECG (EKG) records heart electrical activity during heartbeat
 - Six limb leads (I, II, III, AVR, AVL, AVF)
 - Six chest leads (V1–V6)
- P wave: **atrial depolarization**
 - PR interval: **beginning of atrial contraction to beginning of ventricular contraction** (time for impulse to reach ventricles from sinus node)
- PR segment: end of P wave to beginning of QRS complex; signifies AV nodal delay
- QRS complex: **ventricular depolarization**
- T wave: **ventricular repolarization**
- QT interval: time from start of Q wave to end of T wave; represents time taken for **ventricular depolarization, repolarization**
- U wave: sometimes seen after T wave (not shown), represents purkinje fiber repolarization

RECORDING ECGs

- Recorded on 1mm graph paper (10mm = 1mV)

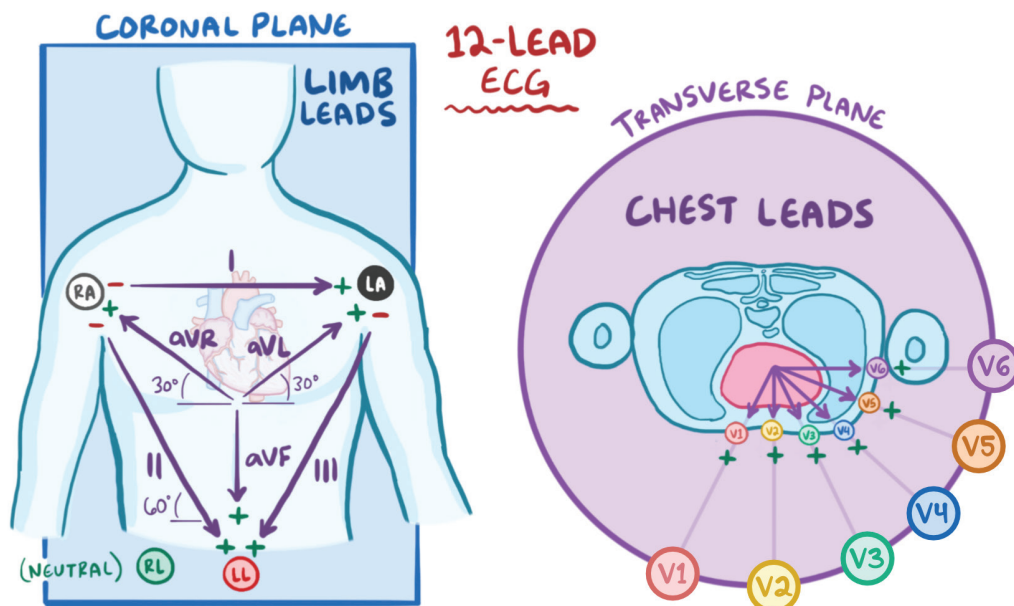


Figure 18.1 Lead placement in the coronal and transverse plane.

- x-axis = time (1mm = 0.04s)
- y-axis = voltage (10mm = 1mV)
- **Limb leads:** I, II, III, AVR, AVL, AVF
 - **Bipolar leads:** I, II, III
 - **Unipolar leads:** AVR, AVL, AVF (augmented voltage for right arm, left arm, left foot)
 - **Lateral leads:** I, aVL, V5, V6
 - **Inferior leads:** II, III, AVF
 - Six limb leads provide six viewpoints of cardiac activity, in frontal plane
- Electrodes placed on shoulders, abdomen to record limb leads
- **Chest leads (precordial):** V1 –V6
 - **Septal leads:** V1,V2
 - **Lateral leads:** V5,V6
 - **Anterior leads:** V3,V4
 - Six chest leads provide six viewpoints of cardiac activity, in horizontal plane

ECG NORMAL SINUS RHYTHM

osms.it/ECG-normal-sinus-rhythm

- P waves precede QRS complexes in 1:1 relationship
- SA node (sinus node), dominant centre of automaticity
 - Normal sinus rhythm 50–90bpm
- Constant RR interval
- Predictable recurring wave pattern (P-waves, QRS, T waves)
- P waves
 - Upright in leads I, II, AVF
 - Amplitude < 2.5mm in limb leads
 - **Sinus arrhythmia:** can be normal if sinus rate varies with respiratory cycle, relatively mild/abnormal if sinus rate varies unpredictably, very dramatic

ECG RATE & RHYTHM

osms.it/ECG-rate-rhythm

RATE DETERMINATION

- **Box method:** measure R-R interval by large boxes
 - **ECG grid:** thick lines 5mm apart (0.20s); thin lines 1mm (0.04s)
 - Locate R wave peak on thick line as “start”
 - **Label blocks (thick lines):** 300; 150; 100; 75; 60; 50
 - Locate next R wave peak to estimate heart rate
- **Fast heart rates:** use fine division within boxes for more accurate estimates
- **Slow heart rates:** use 2.5s marks at top of trace paper
 - Locate R wave peak on large block line as “start”
 - Count subsequent number of complete R waves in 10s strip (total strip)
- To calculate heart rate
 - Count number of QRS complexes across entire recording, multiply by six for heart rate; used to estimate heart rate during irregular rhythms

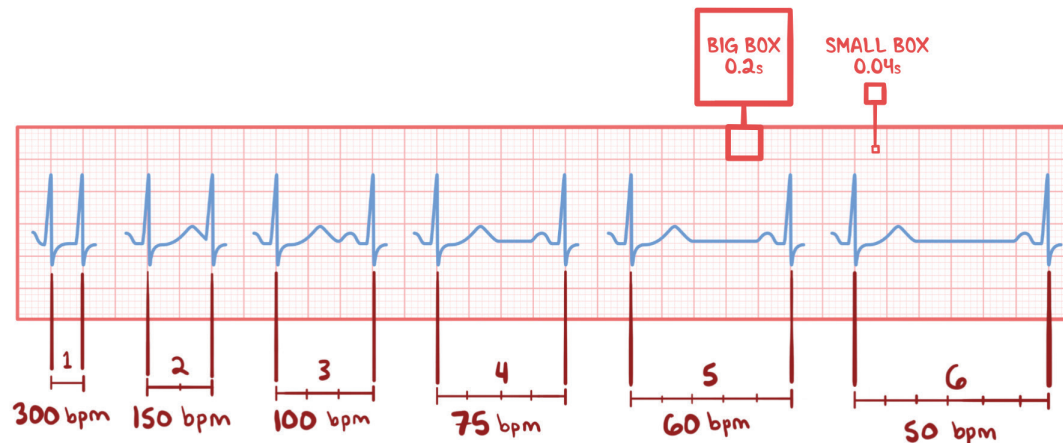


Figure 18.2 The Box method measures distance between R-R intervals to calculate the heart rate.

ECG INTERVALS

osms.it/ECG-intervals

PR INTERVAL & SEGMENT

- Normal interval 0.12–0.20s
 - Measure duration(s) from start of P to start of Q
- Normal segment:** usually isoelectric, may be displaced

- QTc interval corrected for heart rate; 0.35–0.44s for normal heart rate (60–100bpm)
- Long QTc (> 500ms) → prone to rapid, potentially fatal ventricular rhythm

QRS INTERVAL

- Normal QRS:** <0.10–0.12s (slight variation between references)
 - Measured from start of Q to end of S
- QRS amplitude (voltage):** wide range of normal limits
 - Low voltage:** < 5mm limb leads, < 10mm chest leads
 - Increased voltage can indicate left ventricular hypertrophy, right ventricular hypertrophy, may be normal
 - Narrow (< 0.12s) / wide (> 0.12s)

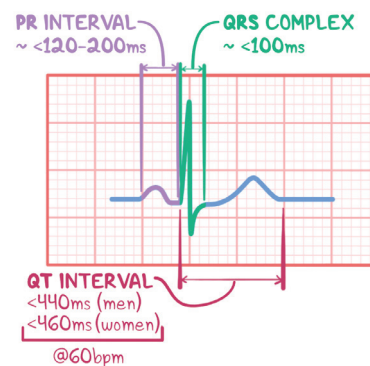


Figure 18.3 An ECG interval includes a segment and one or more waves and should be completed within a specific amount of time to be considered healthy.

QT INTERVAL

- Normal QT < 50% RR interval, only for normal heart rates
- Measure QT from start of Q to end of T
- Measure RR interval as time between R-R

ECG AXIS

osms.it/ECG-axis

- Mean direction (vector) of ventricular depolarization wavefront
 - Mean QRS vector normally downward from AV node through stronger left ventricle
- Normal axis range -30° to $+90^{\circ}$ of frontal plane
- Limb leads indicate vector deviation in frontal plane
 - Divided into four quadrants

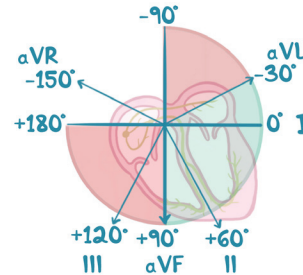


Figure 18.4 The green shows a normal range. The red bottom left quadrant would indicate right ventricular hypertrophy while the top right would indicate left ventricular hypertrophy.

ECG TRANSITION

osms.it/ECG-transition

- Chest leads provide information on vector rotation in horizontal plane
 - **Normal:** gradual transition of QRS through leads V1–V6
 - QRS complex switches from predominantly negative to positive either between V2, V3 or between V3, V4

R WAVE PROGRESSION

- **Early:** tall R wave in V1, V2
- **Delayed R:** transition point between V4, V5/between V5, V6
 - R amplitude > S; no progression through V5, V6
- **Reverse:** decreasing amplitude

ASSESSMENT FOR NORMAL REGULAR RHYTHM

- Is there a P before every QRS complex?
- Is there a QRS after every P?
- Are the P waves normal?

ABNORMAL RATES & RHYTHMS

- Conventionally defined, sinus bradycardia <60bpm
 - True normal adult resting heart rate is 50–90bpm
- Sinus tachycardia > 100bpm
- If SA node fails, other latent ectopic pacemakers capable of automaticity
 - Atria, AV junction, His bundle, bundle branches can set heart rate
 - Each foci has unique rate (atrial foci 60–80bpm; junctional foci 40–60bpm; ventricular foci 20–40bpm)
 - **Overdrive suppression:** mechanism by which only foci/node with highest firing frequency rate conducts impulses, suppresses other pacemaker sites

Heart blocks

- Sinus block
 - SA node temporarily ceases to conduct impulse; usually resumes, may cause escape rhythm

- AV block
 - **First degree:** prolonged PR interval > 0.2s
 - **Second degree:** some P waves conducted to ventricles, followed by QRS complex while some not
 - **Third degree:** atria, ventricles beat asynchronously with no conduction through AV node (complete dissociation between P, QRS complexes)
- **Bundle branch blocks**
 - Left bundle branch block (LBBB)
 - Activation of left ventricle delayed causing left ventricle to contract later than right ventricle
 - Broad QRS < 120ms
 - Secondary R wave (R') in leads V1-3
 - Slurred S wave in lateral leads (I, aVL, V5-6)
 - Secondary repolarization abnormalities in right precordial leads (ST depression, T wave inversions)
 - Right bundle branch block (RBBB)
 - Activation of right ventricle delayed causing right ventricle to contract later than left ventricle
- Broad QRS < 120ms
- Dominant S wave in V1
- Absence of Q waves, broad monophasic R wave in lateral leads
- Left anterior fascicular block
 - Impulses conducted to left ventricle via left posterior fascicle
 - Left axis deviation
 - Increased R wave peak time in aVL
 - Small Q waves, tall R waves in leads I, aVL
 - Small R waves, deep S waves in leads II, III, aVF
 - Increased QRS voltage in limb leads
 - Prolonged R wave peak time in aVL > 45ms
- Left posterior fascicular block
 - Impulses conducted to left ventricle via left anterior fascicle
 - Right axis deviation
 - Increased R wave peak time in aVF
 - Small R waves with deep S waves in leads I, aVL
 - Small Q waves with tall R waves in leads II, III, aVF
 - Increased QRS voltage in limb leads

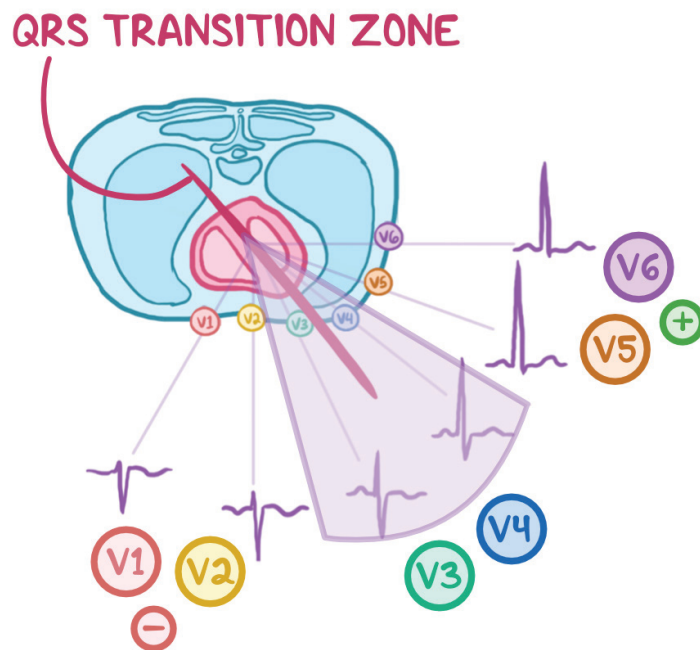


Figure 18.5 The QRS transition zone usually occurs in the V3 and V4 lead. V1 and V2 are mostly positive while V5 and V6 are mostly negative.

ECG CARDIAC HYPERTROPHY & ENLARGEMENT

osms.it/ECG-cardiac-hypertrophy-enlargement


ATRIAL DILATION/ENLARGEMENT

- Biphasic P waves > one small box in lead V1
- Initial component of wave larger
 - Right atrial enlargement
- Terminal component of wave larger
 - Left atrial enlargement
- Amplitude of P wave in any limb lead > 2.5mm
 - Probable right atrial enlargement

- Sum of S wave depth in V1 + R wave height in either V5/V6 > 35mm
- Possible left axis deviation
- Left ventricular 'strain pattern'
 - Downsloping ST segments, T wave inversions in lateral leads

RIGHT VENTRICULAR HYPERTROPHY

- V1–V6 all consisting of small r waves, deep S waves (no R wave transition)
- Tall R wave in V1 that progressively shortens across to V6 (reverse R wave transition)
- Possible right axis deviation



LEFT VENTRICULAR HYPERTROPHY

- Deep S wave in lead V1
- Tall R wave in V5 and/or V6

Figure 18.6 Hypertrophy is an enlargement of the muscle wall while an increase in volume is known as dilation.

CHARACTERISTICS of CARDIAC HYPERTROPHY

	LEFT	RIGHT
ATRIAL ENLARGEMENT	V1: Biphasic P, II: Double-Humped	II & V1: Big P
VENTRICULAR ENLARGEMENT	V1: Big R; V5: Big S	V1: Huge S; V5 & V6: Huge R

ECG MYOCARDIAL INFARCTION & ISCHEMIA

osms.it/ECG-cardiac-infarction-ischemia

MYOCARDIAL INFARCTION

- Complete/partial blockage in coronary artery causing myocardial damage
- ST elevation MIs (STEMIs): complete artery blockage
 - ST elevation present on ECG; emergency
- Non-ST elevation MIs (NSTEMIs): partial artery blockage
 - ST elevations not present on ECG
 - Less emergent than STEMI

ISCHEMIA

- Inverted T waves; slight to deep; most pronounced in chest leads
- Angina: transient T wave inversion; may occur without infarction
- Inverted T wave in any leads V2–V6 are abnormal
 - Suggest ischemia, variety of other pathologies
- Acute or recent infarction: elevated ST segment (slight to extensive)
 - One of the earliest ECG signs of infarction
 - Returns to baseline over time
- Restricted coronary blood flow: flat depressed ST segment
 - Suggests subendocardial infarction; any ST depression

NECROSIS

- Pathologic Q wave; > 0.04s, amplitude < $\frac{1}{3}$ - $\frac{1}{4}$ mm the R wave height
 - Non-pathological q waves < 0.04s considered normal
- Ignore AVR lead; record leads with Q (pathological), q (physiological) waves; ST depression/elevation; inverted T waves
- Anterior left ventricular infarction (q in V5, V6)
 - Chest leads anterior location; Q waves in leads V1, V2, V3 /V4
- Posterior infarction
 - Large R in leads V1, V2; possible Q in V6
 - Mirror test: invert, examine reflection for vQ, ST elevation in leads V1, V2
- Lateral infarction: Q in leads I, AVL
- Inferior infarction: Q in leads II, III, AVF

ECG CHARACTERISTICS of COMMON ARRHYTHMIAS

	ISCHEMIA	INFARCTION
SUBENDOCARDIAL	Stable angina; ST Depressions	Unstable angina; NSTEMI; ST Depressions; T wave Inversion
TRANSMURAL	Unstable angina; NSTEMI; ST Depressions; T wave Inversion	STEMI; T wave inversions; Hyperacute T waves; ST elevation; Pathologic Q waves