



NOTES LEUKEMIAS

GENERALLY, WHAT ARE THEY?

PATHOLOGY & CAUSES

- Malignant neoplastic monoclonal proliferation of hematopoietic blood cells
- Abnormal blood cells/precursors accumulate in bone marrow → physical suppression → prevent maturation

TYPES

Acute

- Acute lymphoid leukemia
- Acute myeloid leukemia

Chronic

- Chronic lymphoid leukemia
- Chronic myeloid leukemia

RISK FACTORS

- Numerical, structural chromosomal aberrations
- Ionizing radiation, chemotherapy
- Benzene exposure

COMPLICATIONS

- Infections, bleeding → death

SIGNS & SYMPTOMS

Cellular maturation absent

- Anemia → fatigue, shortness of breath, pallor
- Thrombocytopenia → bruising, petechiae, epistaxis
- Neutropenia → bacterial infections → fever, pneumonia, sepsis

Neoplastic infiltration

- Bone marrow
 - Bone pain
- Thymus
 - Palpable mass, airway compression
- Liver and spleen
 - Hepatosplenomegaly
- Lymph nodes
 - Lymphadenopathy
- Meningeal infiltration
 - Headaches, vomiting, nerve palsies, nuchal rigidity

DIAGNOSIS

LAB RESULTS

- Blood count
- Blood smear
- Bone marrow smear
- Immunophenotyping

TREATMENT

MEDICATIONS

- Chemotherapy

SURGERY

- Bone marrow transplantation

OTHER INTERVENTIONS

- Radiation therapy

ACUTE LYMPHOID LEUKEMIA (ALL)

osms.it/acute-lymphoid

PATHOLOGY & CAUSES

- Neoplastic monoclonal proliferation of lymphoid stem cells (lymphoblasts) in bone marrow
- Immature lymphoblasts accumulate in bone marrow → physical suppression → prevent maturation

TYPES

B cell acute lymphoblastic leukemia (B-ALL)

- Most common (85%)
- Origin
 - Pre-B cells of bone marrow
- Associated with translocations t(12,21), t(9,22)

T cell acute lymphoblastic leukemia (T-ALL)

- Origin
 - Pre-T cells in thymus
- Associated with NOTCH1 mutation

RISK FACTORS

- **Young age** (most common leukemia in children)
 - B-ALL: peak incidence at three years old
 - T-ALL: peak incidence at 15–20 years old
- **Down syndrome** (after age five)
- Radiation exposure

SIGNS & SYMPTOMS

- Abrupt onset

Cellular maturation absent

- Anemia → fatigue, shortness of breath, pallor
- Thrombocytopenia → bruising, petechiae, epistaxis

- Neutropenia → bacterial infections → fever, pneumonia, sepsis

Neoplastic infiltration

- Bone marrow
 - Bone pain
- Thymus
 - Palpable mass, airway compression
- Liver and spleen
 - Hepatosplenomegaly
- Lymph nodes
 - Lymphadenopathy
- Meningeal infiltration
 - Headaches, vomiting, nerve palsies, nuchal rigidity

DIAGNOSIS

LAB RESULTS

Blood count, smear of peripheral blood

- ↑ lymphoblasts
- ↑ white blood cells

Bone marrow smear

- Hypercellular bone marrow, lymphoblast domination (> 20%)
- T-ALL
 - “Starry sky” pattern produced by phagocytosing macrophages
- Mitotic figures

Immunophenotyping

- Terminal deoxynucleotidyl transferase (TdT)
 - **Positive nuclear staining**, distinguish from acute myeloid leukemia (AML)
- B-ALL
 - Express tumor markers **CD10, CD19, CD20**
- T-ALL
 - Express tumor markers CD1, CD2, CD5, CD7, CDH

TREATMENT

MEDICATIONS

- Aggressive chemotherapy with prophylactic injections to scrotum, cerebrospinal fluid (CSF)
 - 95% complete remission, 75% cure rate
 - More successful in children > two years old
- If spread to brain
 - Intrathecal chemotherapy/radiation therapy
- Tyrosine-kinase inhibitors



MNEMONIC: ABCDE Characteristics of Acute leukemias

Acute:
Blasts predominate
Children
Drastic course
Elderly
Few WBC's (+ Fevers)

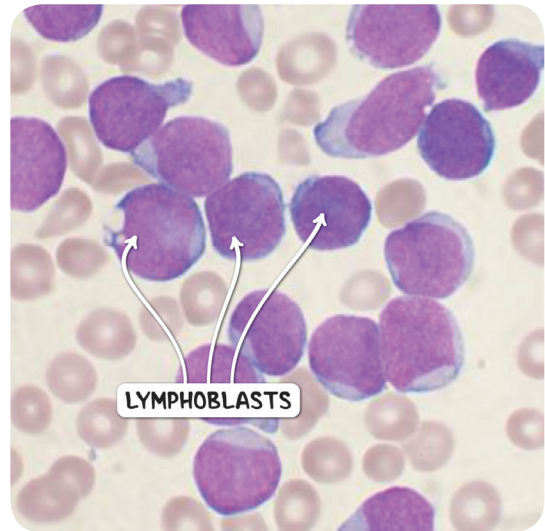


Figure 48.1 A bone marrow film from an individual with acute lymphoid leukemia.

ACUTE MYELOID LEUKEMIA (AML)

osms.it/acute-myeloid

PATHOLOGY & CAUSES

- Neoplastic monoclonal proliferation of myelogenous stem cells (myeloblasts) in bone marrow
- Immature myeloblasts accumulate in bone marrow → physical suppression → prevents maturation

TYPES

Acute promyelocytic leukemia

- Associated with translocation t(15,17) → disruption of retinoic acid receptor → promyelocytes accumulate

Acute monocytic leukemia

Acute megakaryocytic leukemia

RISK FACTORS

- Adults age; peak at 60
- Radiation, chemotherapy
- Myeloproliferative disorders
- Down syndrome (before age five)

COMPLICATIONS

- Disseminated intravascular coagulation (DIC)

SIGNS & SYMPTOMS

- Abrupt onset

Cellular maturation absent

- Anemia → fatigue, shortness of breath, pallor
- Thrombocytopenia → bruising, petechiae, epistaxis
- Neutropenia → bacterial infections → fever, pneumonia, sepsis

Neoplastic infiltration

- Symptoms less common in AML than ALL
- Bone marrow
 - Bone pain
- Thymus
 - Palpable mass, airway compression
- Liver and spleen
 - Hepatosplenomegaly
- Lymph nodes
 - Lymphadenopathy
- Meningeal infiltration
 - Headaches, vomiting, nerve palsies, nuchal rigidity

Neoplastic infiltration

- Symptoms more common in AML than ALL
- Skin
 - Leukemia cutis
- Gums
 - Swelling (classic)

DIAGNOSIS**LAB RESULTS****Blood count, blood smear**

- ↑ leukocytes, anemia

Bone marrow smear

- ↑ myeloblasts > 20%
- Myeloblasts containing Auer rods (aggregates of myeloperoxidase)

TREATMENT**MEDICATIONS**

- Chemotherapy
- All-trans retinoic acid treatment
 - For promyelocytic leukemia

SURGERY

- Bone marrow transplantation

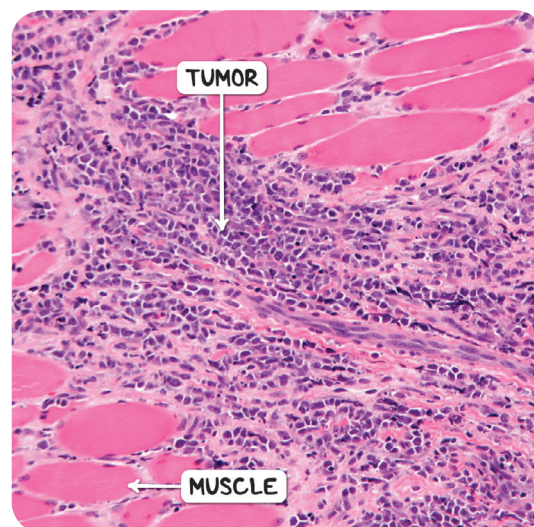


Figure 48.2 The histological appearance of a myeloid sarcoma, also known as a chloroma. The tumor is an extramedullary manifestation of acute myeloid leukemia.

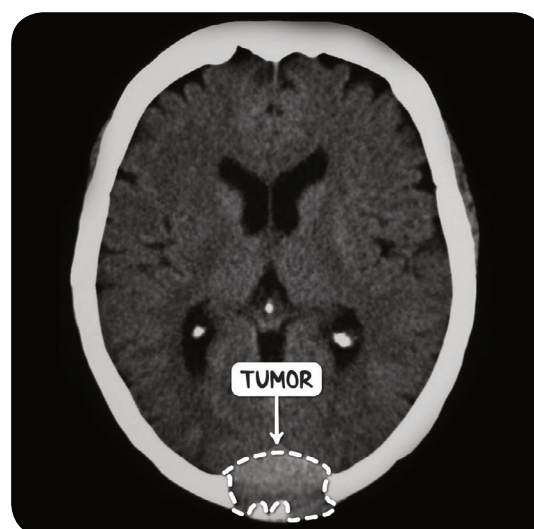


Figure 48.3 A CT scan of the head in the axial plane demonstrating a myeloid sarcoma, or chloroma, of the occiput. The tumor is extradural and destroying the overlying bone.



MNEMONIC: ABCDE

Characteristics of Acute leukemias

Acute:

Blasts predominate

Children

Drastic course

Elderly

Few WBC's (+ Fevers)

CHRONIC LYMPHOID LEUKEMIA (CLL)

osms.it/chronic-lymphoid

PATHOLOGY & CAUSES

- Neoplastic monoclonal proliferation of mature, functionally abnormal B lymphocytes in bone marrow, blood
- Mature B lymphocytes accumulate in bone marrow → physical suppression → prevent maturation

CAUSES

- Chromosomal abnormalities
- Mutation of proteins involved in tyrosine kinase pathway (e.g. Bruton's tyrosine kinase)

RISK FACTORS

- **Adult age**; most common leukemia in adults
- Family history
- Agent Orange exposure

COMPLICATIONS

- Abnormal Ig secretion
 - Hypogammaglobulinemia, autoimmunity (e.g. autoimmune hemolytic anemia)
- Richter syndrome
 - Progresses into **aggressive lymphoma** (e.g. diffuse large B cell lymphoma)

SIGNS & SYMPTOMS

- Late onset

Cellular maturation absent

- Anemia → fatigue, shortness of breath, pallor
- Thrombocytopenia → bruising, petechiae, epistaxis
- Neutropenia → bacterial infections → fever, pneumonia, sepsis

Neoplastic infiltration

- Symptoms less common in AML than ALL
- Bone marrow
 - Bone pain
- Thymus
 - Palpable mass, airway compression
- Liver and spleen
 - Hepatosplenomegaly
- Lymph nodes
 - Lymphadenopathy
- Meningeal infiltration
 - Headaches, vomiting, nerve palsies, nuchal rigidity

DIAGNOSIS

LAB RESULTS

Blood count, blood smear

- Lymphocytosis $> 5,000$ per mm^3
- **Smudge cells:** disruption of fragile cell membranes of abnormal lymphocytes

Immunophenotyping

- CD5, CD20, CD23

OTHER DIAGNOSTICS

Surgery

- Lymph node biopsy
 - \uparrow small, round lymphocytes infiltration
 - Proliferation centers (pathognomic)

TREATMENT

MEDICATIONS

- Chemotherapy
- Immunotherapy

SURGERY

- Bone marrow transplant

OTHER INTERVENTIONS

- Radiation therapy

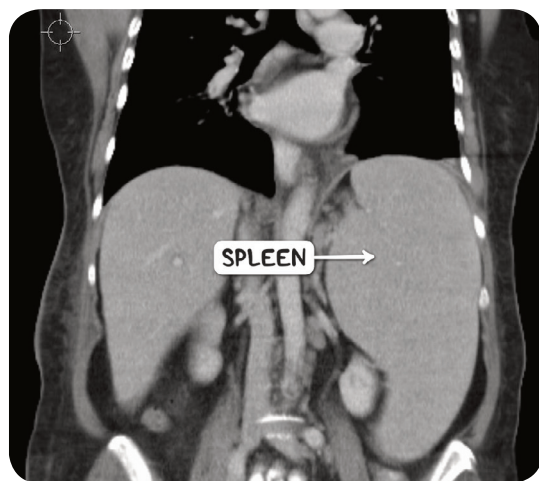


Figure 48.6 A CT scan in the coronal plane demonstrating splenomegaly as a consequence of chronic lymphoid leukemia.

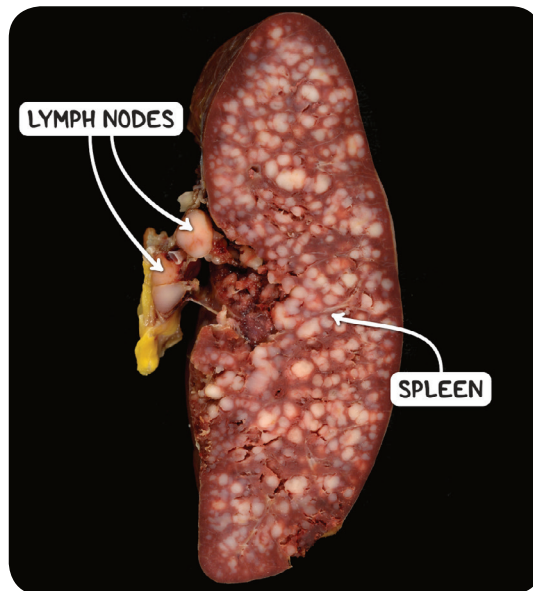


Figure 48.4 The gross pathological appearance of the spleen in a case of chronic lymphoid leukemia. The lymph nodes at the hilum of the spleen are also involved.

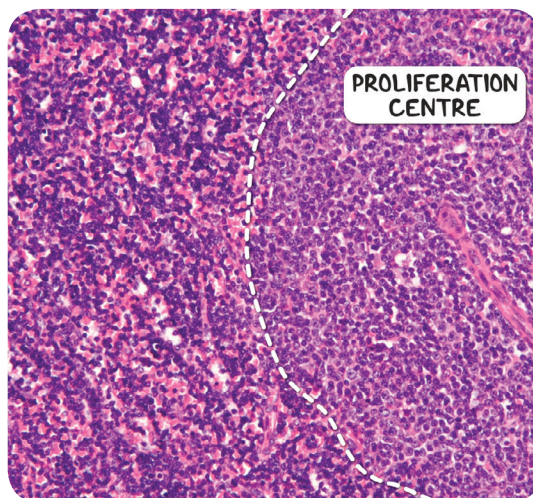


Figure 48.5 The histological appearance of chronic lymphocytic leukemia. There is a proliferation centre (also known as a pseudofollicle) composed of malignant lymphocytes with bigger, larger nuclei. This proliferation centre is surrounded by small, darker staining lymphocytes.

CHRONIC MYELOID LEUKEMIA (CML)

osms.it/chronic-myeloid

PATHOLOGY & CAUSES

- Neoplastic monoclonal proliferation of mature granulocytes/precursors
- Mature granulocytes accumulate in bone marrow → physical suppression → prevent maturation
- Associated with **Philadelphia chromosome** t(9, 22) → BCR-ABL1 fusion → chimeric protein with strong tyrosine kinase activity (> 90% of individuals)

RISK FACTORS

- **Adult age** (> 40 years), **radiation exposure**, **benzene exposure**

SIGNS & SYMPTOMS

- Classified by clinical signs, lab results

Chronic phase (85% at time of diagnosis)

- Leukocytosis (predominantly neutrophils)
- Asymptomatic/non-specific symptoms
 - Fatigue, weight loss, loss of energy, fever

Accelerated phase

- > 20% basophils in blood/bone marrow
- 10–19% myeloblasts in blood/bone marrow
- Anemia
- Splenomegaly, hepatomegaly, lymphadenopathy
- Recurrent infections
- Bleeding, petechiae, ecchymoses
- Treatment less effective

Blast crisis

- Terminal phase; rapid progression, low survival rate
- > 20% myeloblasts/lymphoblasts in blood/bone marrow

- Increasing anemia, thrombocytopenia, basophilia
- Bone pain, fever
- Significant splenomegaly

DIAGNOSIS

LAB RESULTS

Blood count, blood smear

- ↑ **granulocytes** (basophils, eosinophils, neutrophils)

Bone marrow biopsy

- Hypercellularity (cells of myeloid cell line/precursors)
- Karyotypic analysis
 - **Fluorescent in situ hybridization (FISH)**, **PCR: BCR-ABL1 gene mapping**
- Mild fibrosis

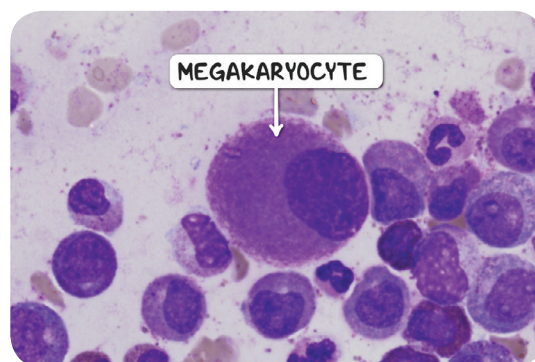


Figure 48.7 A bone marrow smear demonstrating a small, hypolobated megakaryocyte, typical of chronic myelogenous leukemia.

TREATMENT

MEDICATIONS

- Tyrosine kinase inhibitors

SURGERY

- Bone marrow transplantation

CHARACTERISTICS OF LEUKEMIA

	ALL	AML	CLL	CML
OCCURRENCE	< 15 years	Majority of adult leukemias	> 50 years	50-60 years
CLASSIFICATIONS	B cell ALL T cell ALL	Promyelocytic, acute, monocytic, megakaryocytic	B cell CLL T cell CLL	Chronic Accelerated Blast
PRIMARY WBC AFFECTED	Lymphocytes	Myeloid, monocytic	Defective, nonfunctional lymphocytes	Granulocytes
LAB RESULTS	↑ lymphoblasts in bone marrow ↑ circulating lymphocytes & lymphoblasts ↓ circulating RBCs, platelets, mature neutrophils	↑ myeloblasts (circulating & bone marrow) ↓ RBCs, platelets, mature neutrophils	↑ circulating lymphocytes ↓ RBCs, platelets, neutrophils	(Circulating & bone marrow) Chronic: ↑ granulocytes, ↑ thrombocytes, 10% blasts Accelerated: ↑ blasts, ↑ basophils, ↓ or ↑ thrombocytes Blast: ↑ blasts, myeloid:erythroid ratio >10:1
CELLULAR CHARACTERISTICS	T-cell ALL: "starry sky" in bone marrow	Auer rods in myeloblasts	Smudge cells in peripheral smear	Pseudo Gaucher cells in marrow
CLINICAL FEATURES	T-cell ALL: mediastinal mass	DIC	Hemolytic anemia	Expanding bone marrow → sternal tenderness
RISK FACTORS	Down syndrome	Down syndrome	Agent orange exposure	Philadelphia chromosome