

NOTES

LOWER RESPIRATORY TRACT INFECTION

GENERALLY, WHAT IS IT?

PATHOLOGY & CAUSES

- Infections involving trachea, bronchi, bronchioles, lungs

RISK FACTORS

- Smoking, compromised immunity, age (children, elderly), comorbidities

COMPLICATIONS

- Respiratory compromise, infection spread, sepsis

SIGNS & SYMPTOMS

- Cough, dyspnea, fatigue, fever

DIAGNOSIS

LAB RESULTS

- Complete blood count (CBC)

Microbe identification

- Blood culture, sputum culture; Gram stain, polymerase chain reaction (PCR)

TREATMENT

MEDICATIONS

- Antimicrobials

OTHER INTERVENTIONS

- Ventilatory support

BACTERIAL TRACHEITIS

osms.it/bacterial_tracheitis

PATHOLOGY & CAUSES

- Rare, potentially life-threatening exudative infection
 - Characterized by mucosal ulceration, pseudomembrane formation, airway obstruction risk (due to edema, exudative sloughing)
- *Common infective agents:* *Staphylococcus aureus*, *Moraxella catarrhalis*, *Streptococcus pneumoniae*, *H. influenzae*

RISK FACTORS

- Antecedent viral infections, especially croup
- Commonly affects children

COMPLICATIONS

- Pneumonia, septicemia, pneumothorax, pneumomediastinum, hypoxia (secondary to airway obstruction), cardiorespiratory arrest

SIGNS & SYMPTOMS

- Prodromal respiratory viral infection presentation → acute onset of fever, hoarseness, sore throat, stridor
- Productive, barking cough with copious tracheal secretions, retrosternal pain
- Progressive respiratory distress
 - Dyspnea, retractions, fatigue, ↓ level of consciousness

DIAGNOSIS

DIAGNOSTIC IMAGING

Chest X-ray

- Upper tracheal narrowing (“steeple sign”)
- Tracheal pseudomembranes (irregular shadows)

LAB RESULTS

- CBC: leukocytosis, left shift

Microbe identification

- Positive tracheal culture, Gram stain

OTHER DIAGNOSTICS

- **Laryngoscopy:** subglottic edema; tracheal lumen narrowing; presence grayish exudate; slough, pus; friable tracheal mucosa

TREATMENT

MEDICATIONS

- Broad antibiotic coverage

OTHER INTERVENTIONS

- Ventilatory support
 - Humidified supplemental oxygen, intubation, endoscopic tracheal debridement
- Fluid management

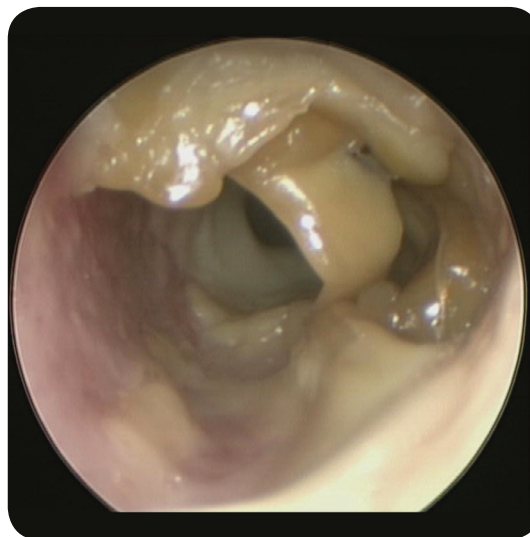

Figure 125.1 The endoscopic appearance of bacterial tracheitis in a nine-year-old boy.

BRONCHIOLITIS

osms.it/bronchiolitis

PATHOLOGY & CAUSES

- Viral small airway respiratory infection
- Viral spread through respiratory secretions, contaminated hands → infects lower respiratory tract cells → natural killer cells attack → cytokines released → epithelial cells produce mucus, vessels vasodilate → fluid leaks, walls swell → airway narrows (more severe in children)

- Dead cells, mucus slide into airway → form mucus plugs → trap air → airways collapse (atelectasis)

CAUSES

- **Respiratory syncytial virus (RSV):** most common, especially during winter months
- Adenovirus, human bocavirus, human metapneumovirus
- *Mycoplasma pneumoniae*

RISK FACTORS

- Young age (children < two years old), previous infection, daycare attendance, decreased immunity, neuromuscular disorders, premature birth, cardiovascular malformations, airway malformations, exposure to smoking

COMPLICATIONS

- Hypoxemia, sepsis

SIGNS & SYMPTOMS

- Congestion, pharyngitis, sore throat, cough
- Hypoxia → tachycardia, tachypnea, exhaustion
- If severe: dyspnea, wheezing, central apnea (brief periodic breathing arrest), nasal flaring, retractions, cyanosis, fever, poor feeding, ↓ activity

DIAGNOSIS

DIAGNOSTIC IMAGING

X-ray

- Patchy infiltrates, atelectasis

LAB RESULTS

- Positive rapid viral testing (RT-PCR): suggests viral infection

TREATMENT

OTHER INTERVENTIONS

Immunoprophylaxis

- **Palivizumab:** monoclonal antibody against RSV given monthly throughout RSV season for prematurely-born infants, chronic lung disease, congenital heart disease
- Heated, humidified supplemental oxygen (high-flow nasal cannula/continuous positive airway pressure (CPAP)), fluids, nasal suctioning
- Intubation (if hypoxia continues despite intervention)

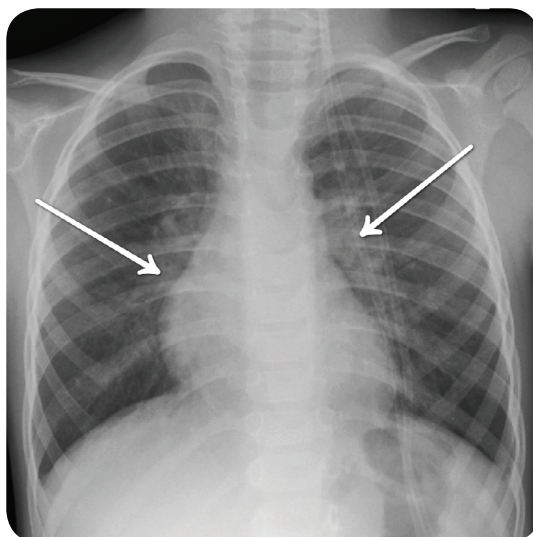


Figure 125.2 A plain chest radiograph in a child with bronchiolitis demonstrating bilateral hilar fullness.

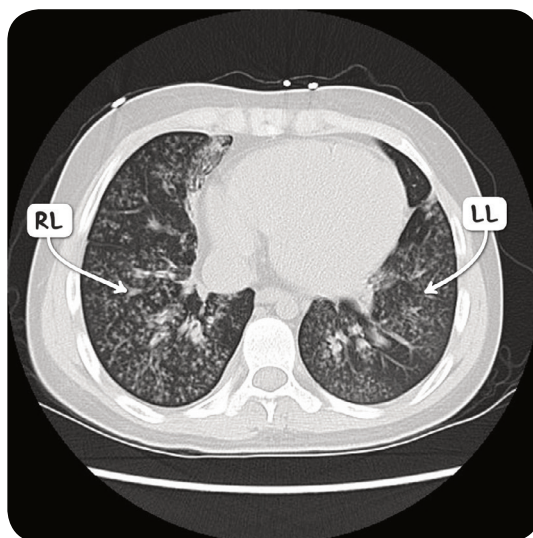


Figure 125.3 A CT scan of the chest in the axial plane in an individual with severe bronchiolitis. Both lung fields demonstrate the tree-in-bud pattern.

COMMUNITY-ACQUIRED PNEUMONIA

osms.it/community-acquired_pneumonia

PATHOLOGY & CAUSES

- Pneumonia acquired outside hospital/healthcare setting
- Viral pneumonia may → superimposed bacterial infection

Spread

- **Respiratory:** from host to host
- **Hematogenous:** from another infection with same pathogen (e.g. cellulitis)

Causative organisms

- *S. pneumoniae*, *S. aureus*, *H. influenzae*, group A streptococci, influenza virus, respiratory syncytial virus (RSV), parainfluenza

RISK FACTORS

- Advanced age, lowered immunity, smoking, alcohol abuse, malnutrition, chronic lung disease

STAGING

Congestion

- Between days 1–2
 - Blood vessels, alveoli start filling with excess fluid

Red hepatization

- Between days 3–4
 - Exudate (contains red blood cells, neutrophils, fibrin) starts filling airspaces → solidifies them → lungs develop liver-like appearance

Gray hepatization

- Approx. days 5–7
 - Lungs remain firm but color changes → red blood cells in exudate start to break down

Resolution

- Approx. day 8, can continue for three weeks
 - Exudate digested by enzymes, ingested by macrophages, coughed up

COMPLICATIONS

- Meningitis, sepsis, pleural effusions

SIGNS & SYMPTOMS

- High fever, cough, hemoptysis, pleuritic chest pain, tachypnea, tachycardia, dyspnea, muscle pain, fatigue
- Crepitation on palpation, dullness on percussion

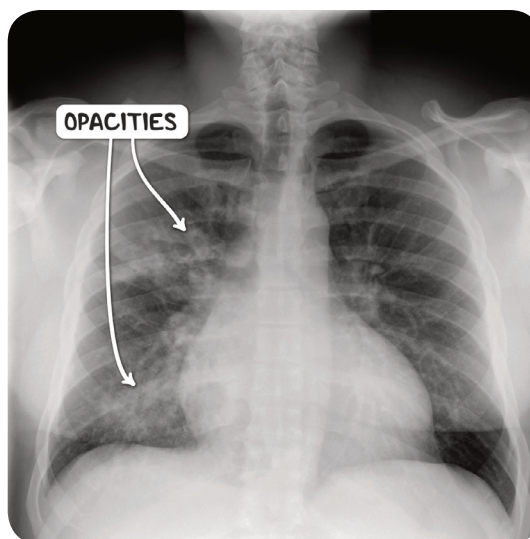


Figure 125.4 A plain chest radiograph demonstrating patchy peri-bronchial shadowing in an individual with bronchopneumonia.

DIAGNOSIS

DIAGNOSTIC IMAGING

X-ray

- Interstitial infiltrates; consolidation; may show pleural effusion

LAB RESULTS

- ↓ oxygen saturation
- CBC: leukocytosis
- **Organism identification:** sputum Gram stain, culture; C-reactive protein test (CRP), PCR for typical viruses
- Positive urine for *S. pneumoniae*

TREATMENT

MEDICATIONS

- Antibiotics

OTHER INTERVENTIONS

- Supplemental oxygen, fluids

Prevention

- 23-valent vaccine (Pneumovax) available against pneumococcus
 - Recommended in splenectomised, immunocompromised individuals

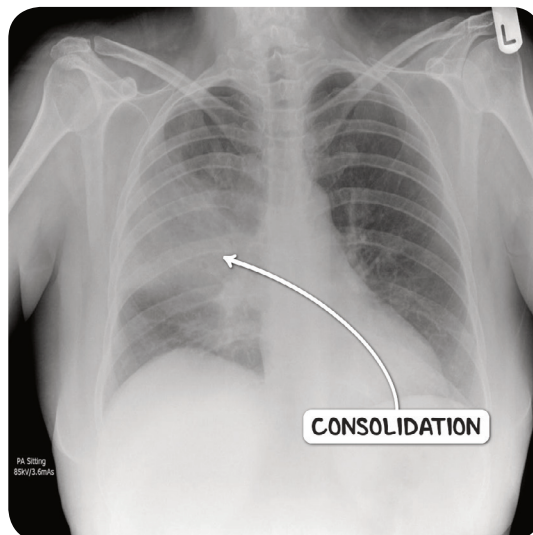


Figure 125.5 A plain chest radiograph demonstrating consolidation of the right middle lobe in an individual with lobar pneumonia.

TYPICAL & ATYPICAL PNEUMONIA PRESENTATIONS

	TYPICAL PNEUMONIA	ATYPICAL PNEUMONIA
CAUSATIVE AGENT	<i>Streptococcus pneumoniae</i>	<i>Mycoplasma</i> , <i>Chlamydia</i> , <i>Legionella</i>
FEVER	High fever	Moderate fever
COUGH	Productive with purulent sputum	Dry cough
PAIN	Chest pain, myalgia	Myalgia, abdominal pain, headache, confusion
RESPIRATION	Crackles, rales, tachypnea, tachycardia	Normal breathing sounds in mild cases
X-RAY	Lobar consolidations	Interstitial presentation, sometimes clear appearance

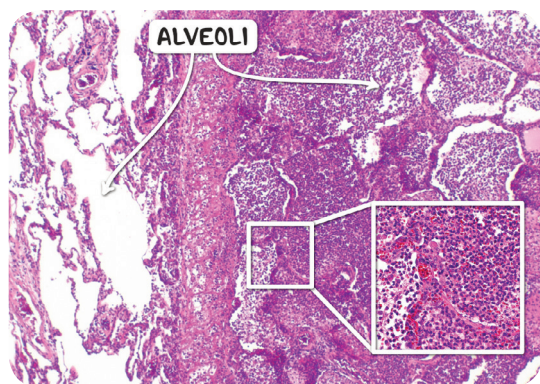


Figure 125.6 The histological appearance of acute pneumonia. In the affected part of the lung (right) the alveoli are filled with neutrophils.

CROUP

osms.it/croup

PATHOLOGY & CAUSES

- Acute respiratory condition
 - Characterized by laryngotracheitis
- Immune response to epithelial viral infection
 - **Upper bronchi:** larynx, **trachea narrow** due to swelling
 - **Lower bronchi:** terminal bronchioles, viral pneumonia

CAUSES

- RSV, **parainfluenza**, adenoviruses
- **Historically:** *Corynebacterium diphtheriae* (vaccine development → ↓ incidence)

RISK FACTORS

- Most common in children < six years old

COMPLICATIONS

- Hypoxia, respiratory failure
- Secondary bacterial infections → ↑ mortality

SIGNS & SYMPTOMS

- Progressive respiratory symptoms; sore throat, hoarse voice (due to laryngeal involvement)
- Respiratory symptoms
 - “barking” cough
 - Tachypnea
 - Grunting (attempt to increase end-expiratory pressure)
 - Prominent inhalation, **inspiratory stridor**, apnea

DIAGNOSIS

DIAGNOSTIC IMAGING

X-ray

- “**Steeple sign**,” narrowing below epiglottis

LAB RESULTS

- CBC: normal ↑ with left shift, or ↓

OTHER DIAGNOSTICS

- Severity: Westley scale 0–17
 - 3–7: moderate
 - 8–11: severe
 - 12 and above: indicates respiratory failure

TREATMENT

MEDICATIONS

- Dexamethasone, epinephrine (nebulized)

OTHER INTERVENTIONS

- Humidified supplemental oxygen, fluids, antipyretics
- Intubation (if impending respiratory failure)

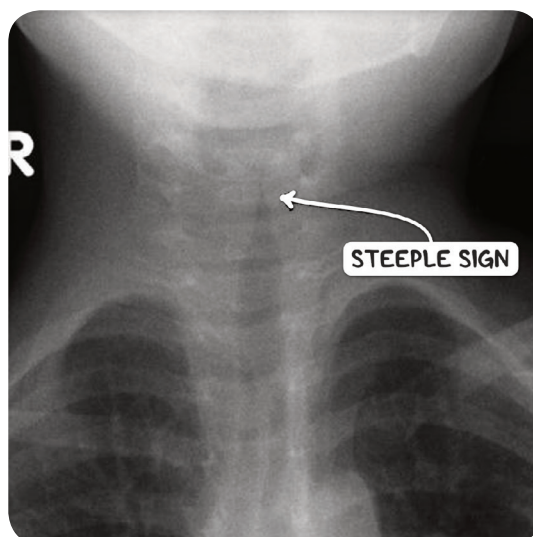


Figure 125.7 A plain X-ray image demonstrating the steeple sign in an infant with croup.

WESTLEY SCORING

	0	1	2	3	4	5
STRIDOR	None	With agitation	At rest			
RETRACTIONS	None	Mild	Moderate	Severe		
CYANOSIS	None				With agitation	At rest
LEVEL OF CONSCIOUSNESS	Normal					Depressed
AIR ENTRY	Normal	Decreased	Markedly decreased			

NOSOCOMIAL PNEUMONIA

osms.it/nosocomial-pneumonia

PATHOLOGY & CAUSES

- Hospital-acquired pneumonia
 - AKA healthcare-associated pneumonia
 - Includes ventilator-associated pneumonia
- Involves microaspiration of organisms from oropharyngeal tract/sometimes from gastrointestinal tract
- Severity varies depending on offending organism, individual's immune system status

CAUSES

- MRSA, *Klebsiella pneumoniae*, *Pseudomonas aeruginosa*, *Acinetobacter*
- Often polymicrobial

RISK FACTORS

- Intubation, poor staff hygiene, contaminated equipment contact

COMPLICATIONS

- Meningitis, sepsis, pleural effusions

SIGNS & SYMPTOMS

- Nonspecific symptoms (malaise, lethargy), fever, productive cough

DIAGNOSIS

DIAGNOSTIC IMAGING

Chest X-ray

- Shows infiltrates

LAB RESULTS

- CBC: leukocytosis, ↑ CRP
- Positive sputum culture

TREATMENT

MEDICATIONS

- Antibiotics

OTHER INTERVENTIONS

- Supplemental oxygen, fluids